

# CAVERNOUS SINUS THROMBOSIS: EXCEPTIONAL COMPLICATION OF ASPERGILLUS ORYZAE NECROTIZING OTITIS EXTERNA

## THROMBOSE DU SINUS CAVERNEUX: COMPLICATION EXCEPTIONNELLE D'UNE OTITE EXTERNE NÉCROSANTE À ASPERGILLUS ORYZAE

R. Kharrat, S. Ayadi, Y. Sghaier, M A. Chaabouni, M.Mnejja, I. Charfeddine

ENT department, Habib Bourguiba University hospital, Sfax Faculty of medicine. 3029 Sfax-Tunisia. University of Sfax, Tunisia. Laboratory deafness, vertigo and cancers, LR23ES01

---

### ABSTRACT

---

**Introduction:** Aspergillus necrotizing otitis externa (NOE) is rare, often diagnosed late, and associated with severe complications.

**Case Report:** A 68-year-old diabetic woman presented with left otalgia and otorrhea which had progressed for 3 months. Initially managed as bacterial NOE, her condition worsened with the onset of headaches and the aggravation of the biological inflammatory syndrome. CT scan showed deep tissue involvement, petrous bone lysis, and cavernous sinus thrombosis. Biopsies identified *Aspergillus oryzae*. Treatment with Voriconazole and anticoagulants led to clinical and biological improvement.

**Conclusion:** Fungal NOE should be considered in antibiotic-resistant cases to prevent serious complications such as cavernous sinus thrombosis.

**Keywords:** Necrotizing otitis externa, Aspergillus, Cavernous sinus

---

### RÉSUMÉ

---

**Introduction:** L'otite externe nécrosante (OEN) à *Aspergillus* est rare, souvent diagnostiquée tardivement, avec un risque élevé de complications.

**Observation:** Une patiente diabétique de 68 ans présentait une otalgie et une otorrhée gauche évoluant depuis 3 mois. Elle a été traitée initialement comme une OEN bactérienne, toutefois, son état s'est aggravé avec accentuation des céphalées et du syndrome inflammatoire biologique. Le scanner a révélé une extension profonde avec ostéolyse de l'apex pétreux et thrombose du sinus caverneux. Les biopsies ont identifié un *Aspergillus oryzae*. Un traitement par Voriconazole et anticoagulants a permis une amélioration clinique et biologique.

**Conclusion:** L'OEN fongique, bien que rare, doit être évoquée en cas d'échec des antibiotiques afin d'éviter des complications graves comme la thrombose du sinus caverneux.

**Mots clés:** Otite externe nécrosante, *Aspergillus*, Sinus caverneux

### INTRODUCTION:

Necrotizing otitis externa (NOE) are caused by fungi in almost 10% of patients, and *Aspergillus* species, essentially *A. flavus* and *A. fumigatus*, are the most common causative fungal pathogens [1,2]. *Aspergillus oryzae* is closely related to *A. flavus* and is known for its economic importance in traditional fermentation industries. Cases of infection due to *A. oryzae* are quite rare [3]. *Aspergillus* NOE is associated with a delay in diagnosis, results in more frequent complications, and tends to be more invasive than the bacterial disease [1]. Complications include mastoiditis, skull base

osteomyelitis, cranial nerve involvement, jugular vein thrombosis (JVT), cerebral venous sinus thrombosis, brain abscess and formation of pseudoaneurysms of the intracranial arteries [2]. Cerebral venous sinus thrombosis is a life-threatening complication of NOE that is seldom reported in the literature. The cavernous sinus is the least common location of cerebral venous thrombosis [4].

Herein, we describe a severe form of *A. Oryzae* NOE in a diabetic patient initially treated with antibiotics and which resulted in cavernous sinus thrombosis.



## CASE REPORT:

A 68-year-old woman with diabetes mellitus presented with a left-sided otalgia and otorrhea evolving for three months despite treatment with oral and topical antibiotics used at home. On presentation, she was afebrile but was unwell and in pain. On otoscopic examination, left external auditory canal was oedematous, congested and stenosed with the presence of granulations and a polyp in its medial part. The tympanic membrane could not be seen. Findings of the remainder of the ENT examination, including neck and cranial nerves were normal. The white blood cell count and CRP level were normal, and erythrocyte sedimentation rate (ESR) was faster-than-normal (95 mm at 1 h). The glycated hemoglobin A1C level was at 8,1% reflecting an inappropriate control of the diabetic condition. Initial culture of swabs from the ear grew resistant staphylococcus aureus. Histological examination of the granulation tissue was reported as chronic inflammatory process but culture failed to grow any bacteria or fungi. The computed tomography (CT) scan without intravenous contrast of the temporal bone at admission showed focal tympanic bone lysis and partial left mastoid air cells and middle-ear cavity opacification (figure 1). A diagnosis of uncomplicated *S aureus* NOE had been made. Treatment was started with intravenous imipenem and vancomycin associated with oral ciprofloxacin, debridement, ear swabs and diabetes control.

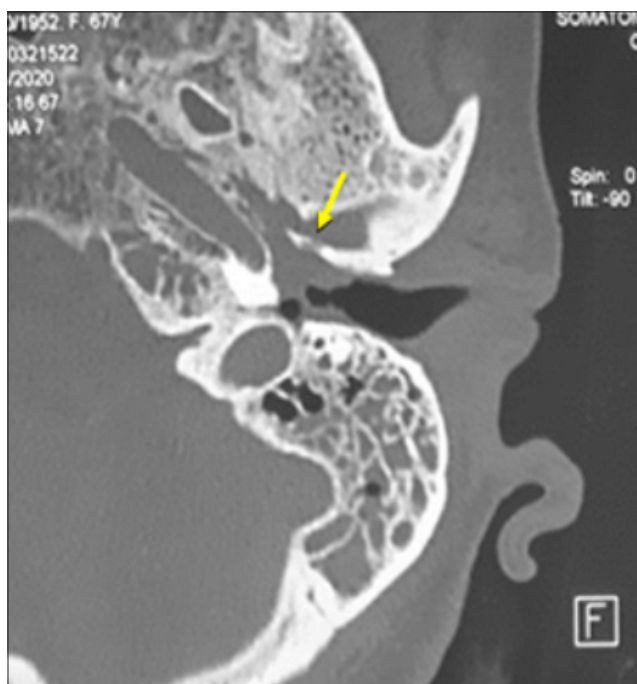Symptoms were worsening despite these empiric antimicrobial therapies with more severe otalgia. She also developed headache without disturbances of consciousness or focal signs. The patient's general condition started to deteriorate. ESR titre also reached 130 mm at the 1st hour.

A repeat CT scan without intravenous contrast of the temporal bones was conducted after a one month course of antibiotics. The scan demonstrated significant progression of the inflammatory process with evidence of new phlegmonous changes of the infra-temporal fossa and parapharyngeal deep neck spaces, involvement of the temporomandibular joint, and bone lysis of the petrous apex. As a cerebral venous sinus thrombosis was suspected at the CT scan, a MRI of the head and the temporal bones was performed. The latter disclosed the same extension of the inflammatory process encasing the external carotid vessel and confirmed a left cavernous sinus thrombosis (figures 2,3). Repeated cultures of swabs for both bacteria and fungi were negative. Biopsy from the granulation tissue was repeated and revealed *Aspergillus Oryzae*.

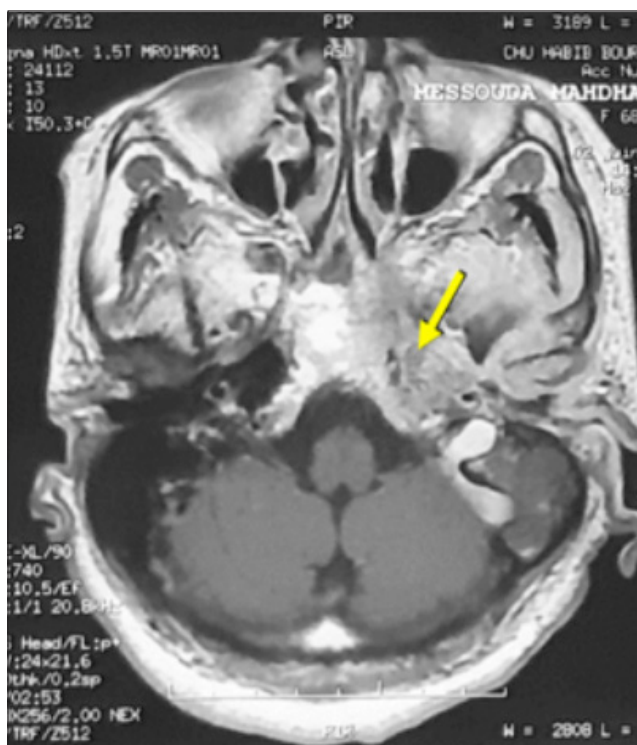
The diagnosis of fungal NOE complicated by cerebral venous sinus thrombosis was established. We stopped intravenous imipenem and vancomycin after 34 days and started oral voriconazole therapy (800 mg the first day, followed by 400 mg/d). We treated the left cavernous sinus thrombosis with subcutaneous enoxaparin initially, followed by transition to oral acenocoumarol, targeted to an INR of 2-3.

Clinically, the patient gradually improved her headache, otalgia and otorrhea, and inflammatory external auditory canal symptoms were relieved.

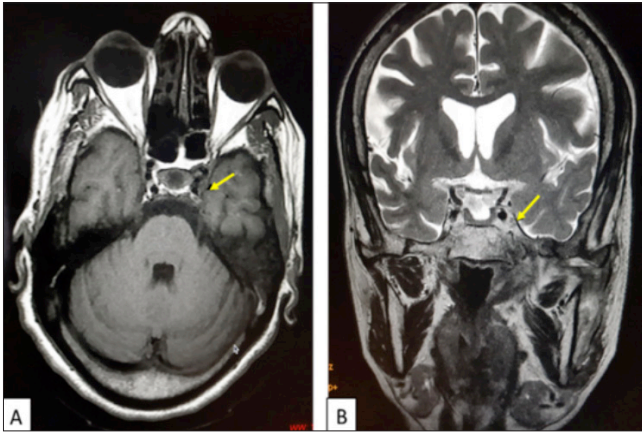
She was discharged after a two-week course of oral voriconazole that we recommended to be continued for at least 8 weeks associated with acenocoumarol for at least 6 months.



**Figure 1:** Axial computed tomography scan of the left temporal bone: focal tympanic bone lysis (arrow) and partial mastoid air cells and middle-ear cavity opacification.



**Figure 2:** Axial cerebral enhanced T1-weighted MRI shows significant extension of the inflammatory process to the infra-temporal fossa and parapharyngeal deep neck spaces, with tympanic bone lysis and temporomandibular joint involvement.



**Figure 3:** Cerebral MRI: thrombosis of the cavernous sinus (arrow): (A): Axial enhanced T1-weighted MRI demonstrating the enhancement defect of the sinus, (B): Coronal T2-weighted MRI shows the thrombus with hypointense signal.

## DISCUSSION:

Aspergillus NOE is a challenging condition with practical clinical questions relating to diagnosis and therapeutic management. In fact, Aspergillus NOE continues to be mistakenly interpreted as a pyogenic disease, and patients are often treated with many failing courses of antibiotics before confirming the diagnosis of Aspergillus NOE [1].

There is no clinical, laboratory or radiological parameter that can distinguish fungal from pyogenic infection. In addition, culturing a fungus from a swab, pus or a superficial biopsy leads to a very low rate of positive results. Actually, deep tissue biopsy remains the gold standard for histological and microbiological invasive aspergillosis diagnosis [1]. In our observation, repeated superficial biopsies were made to confirm the presence of fungal material which confirms their limitations. Furthermore, the phenotyping of fungus is often challenging with the classical approaches. Molecular methods, when provided, are recommended for identification of individual species within the various Aspergillus sections, especially in the cases when the classical approaches fail to identify the Aspergillus species. More recently, the effectiveness of MALDI-TOF and PCR sequencing has also been reported [3]. In our patient, *A. oryzae* was found. *A. Oryzae* is considered as a non-pathogenic fungus but may, like many other harmless microorganisms, grow in human tissue under exceptional circumstances, essentially in debilitated patients [3]. In our knowledge, no case in the literature of NOE with *A. Oryzae* has been reported. All these diagnosis difficulties had lead some teams to consider fungal NOE in patients who are unresponsive to or relapse after antibiotic therapy [5].

Fungal NOE tends to be more invasive than the bacterial disease and subsequently results in numerous complications [1]. The infection may spread medially to the jugular foramen and JVT may then occur secondary to inflammation [2], and so cases of Lemierre's syndrome were also reported [6]. We reported a severe clinical phenotype with vascular

involvement with a cavernous sinus thrombosis, not described previously. From a physiopathological point of view, thrombosis may be explicated by that diabetic microangiopathy affect the natural local host defenses and enhance the propensity for Aspergillus to invade blood vessel walls. Additionally, diabetes can alter systemic immune function through impairment of IL-17 immunity that is involved in the control of fungal invasion [5]. In case of cavernous thrombosis, all cranial nerves passing through the cavernous sinus (III, IV, V1, V2, VI) can be affected [4]. This complication often presents with fever, headache and / or eye findings such as periorbital swelling and ophthalmoplegia [7]. In our case, the patient presents a severe headache but cranial nerves examination was normal. Early diagnosis and appropriate treatment are important to prevent complications and neurological sequelae [7,8]. The management of complicated NOE is based on three main axes, which are symptomatic treatment, the complication treatment and etiological treatment which represent the main component [7]. Since 2002, voriconazole has become the primary treatment of aspergillosis NOE, because of its efficiency and its good bone diffusion [5]. Concerning the length of voriconazole therapy, the guidelines of the Infectious Diseases Society of America for treatment of Aspergillus infections recommend a minimum duration of 6 to 8 weeks [9]. In our institute, patients usually receive 6 to 8 weeks of antifungal therapy, and more if clinical examination or imaging control supports extending treatment. In our case, we decided to discontinue antifungal therapy after the minimum duration of 8 weeks, on the basis of PET-CT findings with regression of the sites of increased uptake.

In the management of the thrombotic complications, an anticoagulation can be safe and may reduce the propagation of thrombus, the mortality and the morbidity [4]. However, it remains so controversial for head and neck infections and there are no evidence for consensus [7]. In a recent meta-analysis, the authors demonstrated that anticoagulation significantly reduces mortality rates (3.3 vs. 18%,  $p = 0.022$ ) [10]. The minimum length of treatment has not been conventionally clarified. The literature reports on different follow-up intervals depending mainly on the underlying disease and the patient's symptoms [4].

## CONCLUSION:

Aspergillus NOE is a rare but serious disease that can lead to severe consequences and may be a life-threatening condition. We underline the importance of considering a fungal etiology in patients with NOE who do not respond to conventional antibiotic treatment. We present this case of NOE resulting in cavernous sinus thrombosis to raise awareness of the possibility of such complication in patients presenting worsening symptoms and severe headache. To prevent this complication, NOE in elderly diabetic individuals should be treated in a well-defined management protocol.



**Funding:** This research did not receive any specific grant from funding agencies in the public, commercial, or not for profit sectors.

**Ethical approval:** Our institution does not require ethical approval for reporting individual cases or case series

**Patient consent:** Written informed consent was obtained from every patient before surgery. No further investigations or additional treatment was needed to

write this article and anonymized patient information was published

**Conflict of Interest Statement:**

The authors have no conflicts of interest to declare

**Data availability statement:** The analyzed data are available on reasonable request.

## REFERENCES:

1. Pichon M, Joly V, Argy N, Houze S, Bretagne S, Alanio A, et al. Aspergillus flavus malignant external otitis in a diabetic patient: case report and literature review. *Infection*. avr 2020;48(2):193-203.
2. Moniot M, Montava M, Ranque S, Scemama U, Cassagne C, Arthur V. Malignant Aspergillus flavus Otitis Externa with Jugular Thrombosis. *Emerg Infect Dis*. avr 2019;25(4):830-2.
3. Sanaz N, Mahdi A, Reza V, et al. Differentiation of Aspergillus flavus from Aspergillus oryzae Targeting the cyp51A Gene. *Pathogens*. 2021 Oct 4;10(10):1279.
4. Nicolien A. van der Poel NA, Mourits MP, de Win MML, Coutinho JM, Dijkers FG. Prognosis of septic cavernous sinus thrombosis remarkably improved: a case series of 12 patients and literature review. *Eur Arch Otorhinolaryngol*. sept 2018;275(9):2387-95.
5. Marchionni E, Parize P, Lefevre A, Vironneau P, Bougnoux ME, Poiree S, et al. Aspergillus spp. invasive external otitis: favourable outcome with a medical approach. *Clin Microbiol Infect*. mai 2016;22(5):434-7.
6. Davidoss N, Ha JF, Anderson JR, Rodrigues S. Lemierre's syndrome – an unusual complication of otitis externa in a young, healthy female. *J Laryngol Otol*. janv 2015;129(S1):S60-2.
7. Faruk Karakeçili, Orçun Barkay, Betül Sümer , et al. Invasive Aspergillosis with Cavernous Sinus Thrombosis Following High-Dose Corticosteroid Therapy: A Challenging Case of Rhino-Orbital-Cerebral Mycosis. *J Fungi (Basel)*. 2024 Nov 13;10(11):788.
8. Alami B, Boujraf S, Quenum L, Oudrhiri A, AlaouiLamrani MY, Haloua M, et al. La thrombose veineuse cérébrale : aspects clinico-radiologiques, à propos d'une série de 62 cas. *JMV-J MédecineVasc*. déc 2019;44(6):387-99.
9. Walsh TJ, Anaissie EJ, Denning DW, Herbrecht R, Kontoyiannis DP, Marr KA, et al. Treatment of aspergillosis: clinical practice guidelines of the Infectious Diseases Society of America. *Clin Infect Dis Off Publ Infect Dis Soc Am*. 1 févr 2008;46(3):327-60.
10. Chatdanai , Nutchar W, Suchanya , Saisawat C. Anticoagulation for cavernous sinus thrombosis: a systematic review and individual patient data meta-analysis. *Eur Arch Otorhinolaryngol*. 2025 Mar;282(3):1127-1134.