

# Reconstructive Frontal Anterior Laryngectomy: Our experience

## Laryngectomie frontale antérieure: Nôtre experience

N. Kolsi, K. Harrathi, S. Jellai, M. Ferjaoui, N. Bouaziz, A. ElKorbi, R. Bouatay, J. Koubaa.

ENT Department at "Fattouma Bourguiba" University- Hospital, Monastir-Tunisia

Received: 2 March 2021; Accepted: 28 March 2021; Published online: 31 April 2021

### ABSTRACT

**Objectives:** to specify the indications of reconstructive frontal anterior laryngectomy (RFAL) with epiglottoplasty in the treatment of glottic laryngeal cancers and to evaluate the functional and oncological findings of this surgical procedure.

**Methods:** A retrospective study of 32 patients who had undergone RFAL over a period of 17 years between 2002 and 2018. We included patients who had a RFAL with epiglottoplasty for T1 and T2 glottic squamous cell carcinoma.

**Results:** twenty five patients were in stage T1a/T1b (78%) and seven patients were in stage T2 (22%). All patients were operated with Tucker Technique. Surgical excision was enlarged to one arytenoid unit in 9 cases (28.1 %).

The median decannulation delay was 19 days [11-52 days]. The first oral feeding tests began between the 8th and 20th postoperative days; with a median refeeding per os delay of 14 days. Median removal time of nasogastric tube and hospital stay was significantly decreased in patients who were decannulated early (J11-J15). Preservation of both arytenoids did not significantly reduce these functional parameters. Median follow-up time was 30.7 months [6-120 months].

**Conclusion:** RFAL with epiglottoplasty is a valuable technique in selected glottic carcinomas. Based on our results, this procedure's local control and survival rates are high with satisfying functional results.

**Key-words:** Glottic carcinoma; Partial laryngectomy; Epiglottoplasty; Tucker.

### RÉSUMÉ

**Objectifs:** préciser les indications de la laryngectomie antérieure frontale reconstructive (LFAR) avec épiglottoplastie dans le traitement des cancers glottiques du larynx et évaluer leur résultats fonctionnels et oncologiques

**Méthodes:** étude rétrospective, sur une période de 17 ans (2002- 2018) ayant inclus 32 patients qui ont eu une LFAR avec épiglottoplastie pour carcinome épidermoïde glottique classé T1 ou T2.

**Résultats:** vingt-cinq patients étaient au stade T1a / T1b (78%) et sept patients étaient au stade T2 (22%). Tous les patients ont été opérés selon la technique de Tucker. L'excision chirurgicale a été élargie à un aryénoïde dans 9 cas (28,1%).

Le délai moyen de décanulation était de 19 jours [11-52 jours]. Les premiers tests d'alimentation orale ont débuté entre le 8e et le 20e jour postopératoire; avec un délai moyen de réalimentation per os de 14 jours. Les délais d'ablation de la sonde nasogastrique et de séjour à l'hôpital étaient significativement diminués chez les patients décanulés précocement (J11-J15). La préservation des deux aryénoïdes n'a pas réduit significativement ces paramètres fonctionnels. La durée médiane de suivi était de 30,7 mois [6-120 mois].

**Conclusion:** RFAL avec épiglottoplastie est une technique efficace dans des indications précises de carcinomes glottiques. Sur la base de nos résultats, le contrôle local et les taux de survie chez les patients opérés selon cette technique sont élevés avec des résultats fonctionnels satisfaisants.

**Mots-clés:** carcinome glottique; Laryngectomie partielle; Épiglottoplastie; Tucker

### INTRODUCTION:

Glottic cancers account for 60% of all laryngeal cancers. More than 90% of them are squamous cell carcinoma [1]. A better understanding of the extension modalities of these cancers has led to the development of various partial laryngectomy surgical techniques that ensure laryngeal preservation.

One major technique is the RFAL with epiglottoplasty; first described by Tucker in 1979 [2]. Since its appear-

ance several authors have adopted this method; hence demonstrating its validity in the treatment of early glottic cancers [3].

However, the treatment of glottic cancers has evolved considerably in recent years with the advent of endoscopic surgery and the evolution of radiotherapy and chemotherapy. Moreover, the development of these different therapeutic options in the literature is done with a double imperative: oncological and functional. This

**Corresponding author:** Kolsi Naourez

**Address:** ENT Department, Fattouma Bourguiba University Hospital, Monastir-Tunisia

**Email:** kolsi.naourez@yahoo.fr



involves determining which therapeutic option provides the best oncological results while preserving the voice and minimizing morbidity. The purpose of this study is to specify the indications of frontal anterior laryngectomy with epiglottic reconstruction in the treatment of glottic laryngeal cancers and to evaluate the functional and oncological findings of this surgical procedure.

## METHODS:

We conducted a prospective study of 32 patients who had undergone RFAL over a period of 17 years between 2002 and 2018 at our ENT Department. We included in the study patients who had a RFAL with epiglottoplasty, for T1 and T2 glottic squamous cell carcinoma. Initial examination was done with indirect laryngoscopy. Extent of the tumor and the mobility of the vocal folds were noted. Also, the neck status was evaluated with manual palpation and cervical CT scan. All patients had cervical computed tomography (CT) with contrast before direct laryngoscopy. All patients were preoperatively examined by suspension laryngoscopy under general anesthesia and were endoscopically examined using 30° and 70° optics to assess possible involvement of the ventricles, the anterior commissure, and the subglottic region. Likewise, we performed biopsies for anatomic-pathological examination. In all cases, we performed panendoscopy to search for a second location. In order to detect abdominal and/or pulmonary metastases to stage the laryngeal cancer, all patients had thoraco-abdominal CT scan or thoracic CT scan associated with abdominal ultrasound. Tumor stages were classified according to the TNM classification designated by the American Joint Committee on Cancer and revised in 2017 (8th edition) [4].

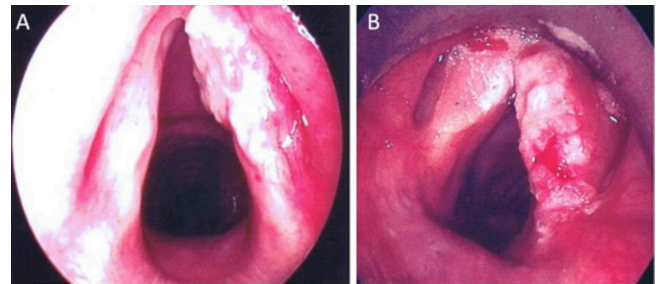
All patients underwent RFAL with Tucker's epiglottoplasty [5,10]. For the functional results of this technique, we specified the delay of oral feeding, removal of the nasogastric tube and decannulation. The quality of the voice was also evaluated. After hospital discharge, patients were followed regularly. A complete ENT and general examination was performed in every clinical visit. A chest x-ray was performed every 12 months looking for lung metastasis. Besides, CT scan, magnetic resonance imaging (MRI) and positron emission tomography (PET) were obtained when necessary. All statistical analyses were performed with SPSS 22.0 for Windows.

## RESULTS:

The average age of patients was 64 years old ranging from 43 to 75 years. We noted a male predominance with a sex ratio of 7.3. A great majority of patients smoked (85%). The combination of alcohol and tobacco was found in 31.2% of all cases. None of our patients were voice professionals. Dysphonia was a constant sign, seen in all patients (100%). This was an isolated dysphonia of recent appearance (85%) or progressive worsening (15%); it was permanent in 75% of cases.

A budding lesion of one or two vocal cords was noted in 23 patients (71.8%). A thickened irregular appearance of a vocal cord was noted in 8 patients (25%), and a whitish keratotic appearance was found in one patient. Touchant

The tumor was unilateral in 24 cases (75%) concerning the right vocal cord in 54% of cases and the left one in 46% of cases. The tumor affected both vocal cords of seven patients (21.8% of the cases under study) and the anterior commissure in one case (Figure.1). The vocal cords were mobile in 93.7% of patients; while a decrease in vocal cord mobility was observed in 2 cases (6.3%). Arytenoid mobility was retained in all cases.

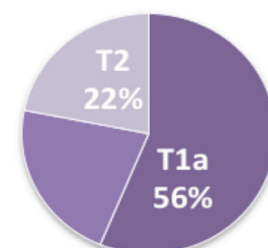


**Figure 1:** Direct laryngoscopy Photos; A: ulcerated infiltrating tumor of the right vocal cord, B: budding tumor of both vocal cords infiltrating the anterior commissure

Cervical lymph node was found in a single patient who had two high jugular-carotid adenopathy, measuring 1.5 and 2 cm in diameter, homolateral to the lesion, mobile in to superficial and deep planes.

Cervical CT scan revealed a thickening of one vocal cord in 24 cases and both of the vocal cords in 7 cases. An anterior commissure invasion was noted in 12 patients. A repression of paraglottic fat was observed in 6 cases. A subglottic extension of less than 5 mm was noted in 4 patients, a supraglottic, a ventricle or a ventricular band extension in four patients. Besides, there were no cases of hyo-thyro-epiglottic (HTE) space invasion or cartilaginous extension.

While 25 of 32 patients had T1 glottic tumors (78%), the remaining 7 patients suffered from T2 glottic tumors (22%). 18 out of 25 cases with T1 stage had tumors with one cord involvement (T1a) and reached the anterior commissure in 12 cases. The remaining 7 cases had tumors involving the anterior commissure partially reaching the opposite cord or covering both cords, extending from the anterior commissure (T1b) (Figure.2).



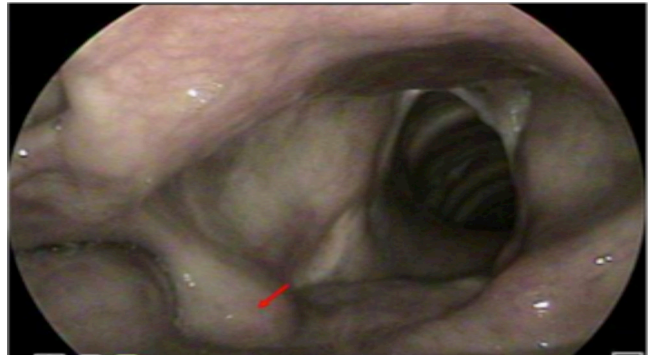
**Figure 2:** classification of patients in our series according to TNM stage



We did not find distant metastasis at the time of diagnosis. Before surgery, patients were psychologically prepared. They were clearly informed about the purpose of the procedure, the probable complications, and the need of a tracheotomy and a nasogastric tube for a few days postoperatively.

All our patients were operated with Tucker operation (Figure.3). Surgical excision was enlarged to one arytenoid unit in 9 cases (28.1 %). We performed lymph node dissection in five cases, in four cases for a T2 tumor with invasion of the ventricle, and in one case for a patient who had cervical lymph node on clinical examination. The definitive anatomopathological examination of cervical lymph node dissection did not show lymph node metastasis in the 5 cases.

The first oral feeding tests began between the 8th and 20th postoperative days with a median delay time of 14 days. The diet began gradually with pasty, then semi-liquid and finally liquid food. The nasogastric tube was removed after the patient could tolerate oral liquids without aspiration. Median removal time of nasogastric tube was 20 days (10 - 33 days); it was 21 days for patients who had a resection of an arytenoid unit and 16 days if both arytenoids are retained. Decannulation was performed after the airway was adequate and the patient had good swallowing functions without aspiration. The median decannulation delay was 19 days (11-52 days). Decannulation was delayed for patients who had postoperative complications, including aspirations and pneumonia. For these patients, the median decannulation time was 30 days. In fact, after the introduction of semi-liquid food, five patients (25%) had aspirations. Two patients kept long-term intermittent aspirations of liquids for more than 3 months (in these two cases, only one arytenoid was retained). Four patients had mild pneumonia due to aspiration which was resolved with medical treatment. No cases of pneumothorax, emphysema or hemorrhagic complications were reported. All of our patients had postoperative endoscopic control with a delay ranging from 12 to 53 days. In the majority of cases, the permeability of the neo larynx was satisfying (Figure.3). An edema of the remaining arytenoids was found in 4 cases.

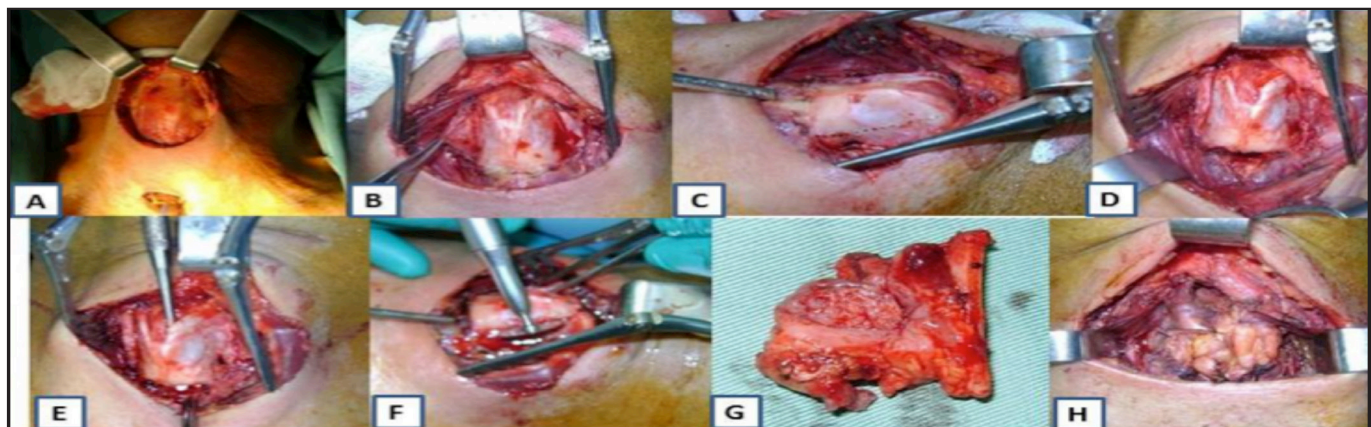


**Figure 4:** Endoscopic view after 04 years of RFAL: laryngeal pathway with satisfying permeability with remaining arytenoid mobile

The average length of stay in hospital was 33 days (18-62 days). It varies mainly depending on the delay of decannulation and the postoperative complications.

When the functional results were analyzed, the mean time for nasogastric tube removal and hospital stay was significantly decreased in 15 patients who were decannulated early (11 to 15 days after surgery) ( $p=0.000$ ). Preservation of both arytenoids did not significantly reduce these functional parameters ( $p>0.05$ )

All patients received speech therapy that began a few days after decannulation and removal of the nasogastric tube. The quality of the voice was judged overall according to its intensity and intelligibility as: good in 60% of cases, medium in 35% of cases and bad in 5% of them. Median follow-up time was 30.7 months (6-120 months). Two patients did not show up at the follow-up period. Thus, oncologic results could be evaluated in the remaining 30 patients. There was one oncologic failure, which means a 5-year actuarial local control rate of 96.7 %. He was a 48-year-old patient who had a stage T2N0M0 lesion (extension to the floor of the ventricle). A massive local recurrence was objectified after 04 years. A biopsy was performed concluding to a thyroid and pre-vertebral location of a well-differentiated squamous cell carcinoma. He had a tracheotomy and received a concurrent radiotherapy and chemotherapy. Subsequently, the patient died of his disease, which makes a 5-year survival rate of 96.7 %.



**Figure 3:** surgical procedure: A: tracheotomy, cervical incision and approach of the larynx. B: the subhyoid muscles were separated in the midline exposing the thyroid cartilage and the perichondrium of the thyroid cartilage was incised in the midline in order to get 2 perichondrial flaps. C: two vertical parallel cuts in the thyroid ala were made. D, E: opening of the cricothyroid and thyrohyoid membrane. F: scissors were placed in the cartilage cut on the less-involved side, opening the larynx from superior to inferior. G: Tumor excision H: reconstruction with epiglottoplasty



## DISCUSSION:

The treatment of early stages of glottic carcinoma is still a challenge in larynx oncology mainly when there is invasion of the anterior commissure which increases the difficulties in achieving safety margins of resection. Therefore, various larynx-preserving strategies are performed such as endoscopic laser microsurgery, transoral robotic surgery, radiotherapy (RT), and open partial laryngectomy as supracricoidal partial laryngectomy or reconstructive frontal anterior laryngectomy (RFAL) with epiglottoplasty [6,7,8,9].

Transoral Laser Microsurgery has made a great progress in recent years in treating larynx carcinoma. However, the challenge remains in determining the adequate resection in the anterior commissure especially in a narrow or prominent larynx (exposure difficulties) [6]. In such cases, radiotherapy could be a good alternative. But we should take into account its high cost and its relative side effects. At our ENT department, RFAL is the treatment indicated for the majority of patients with early stage glottic cancer. This open surgical technique has the advantage to allow the preservation of one or both arytenoid units, with a favorable functional innervation for phonation and swallowing; providing simpler surgical suites than in other supracricoid laryngectomies [11;12;13]. In our series, we performed RFAL for glottic carcinomas T1 (T1a and T1b), with extension to the anterior commissure or T2 cancers with reduced cordal mobility. The exeresis of the arytenoid was practiced in 28.1 % of cases. When the lesion of the vocal cord is anterior, it is possible to preserve both arytenoids in 71.9% of cases in our series)

For Zanaret and Tucker, the indications concern: unilateral cancers of the vocal cords either extending to the vocal process of an arytenoid, reaching the anterior commissure, or laying below the glottic region with an extension of less than 1 cm; bilateral tumors of the vocal cords with or without invasion of an arytenoid (provided that the extension of the tumor to the contra-lateral vocal cord does not exceed 50% of the length of the cord); small localized tumors involving the ventricle and the lower part of the homolateral ventricular band and as a salvage treatment after failure of previous treatment for T1 and T2 tumors [2,13].

An Australian team [14] had identified RFAL's indications as: large T1 glottic tumors; T2 tumors with supraglottic or subglottic extension; difficult exposure of early glottic cancers for endoscopic gesture; wide planned resection, extended both in the anterior and posterior as well as beyond the glottic floor.

For many authors, laryngeal immobility is a contraindication of RFAL: Zanaret and Mallet considered that T3 glottic cancers should not be operated by this technique [3,13]. Other authors indicated surgery if the vocal cord had a reduced mobility without arytenoid invasion[12,13]. Chawla noted that failure rates were high for tumors with impaired cordal mobility secondary to paraglottic extension [14].

It is noteworthy that for some authors [3,11] a subglottic

extension above 0.5 mm is a contraindication to the RFAL. Tucker performed The RFAL for eight patients with a subglottic extension greater than 1 cm [10]. Only one patient had a local recurrence and was caught up by a totalization of laryngectomy. In our study, endoscopy and cervical CT scan evoked subglottic posterior extension (less than 05mm) in four cases; it was not objectified on definitive histological examination.

According to some authors the supraglottic extension was a contraindication to the RFAL[13,14,15]. They considered, the invasion of the ventricle exposed to a high risk of recurrence and resection was often oncologically insufficient. In our study, four patients had glottic cancer extended to the supraglottic region. Histological examination confirmed ventricular invasion in two cases, and none had a recurrence.

Several authors considered that the laryngeal anterior commissure cancers (1% of glottic cancer) should be differentiated from the glottic cancer extending to the anterior commissure [16, 17, 18]. For Bradley [18], the anterior commissure cancers had a high risk of stage underestimation (25% to 50% of cases) with the possibility of cartilage and microscopic supraglottic extension.

In the literature, the invasion of the anterior commissure was estimated at 20%[19]. In our study, anterior commissure was involved in 12 cases (37.5 %). In only one case, the tumor had originated at the anterior commissure.

Glottic cancers reaching the anterior commissure are a real challenge for both diagnosis and treatment. A considerable rate of therapeutic failure was noted. Giovanni [19] indicated RFAL for tumors that didn't exceed the glottic plane and invaded the anterior commissure. Prades [5] preferred supracricoid laryngectomy for tumor starting from the anterior commissure.

As RFAL is a functional partial laryngectomy with more or less heavy consequences, it is therefore necessary to consider other contraindications related to operability and patient's condition. These contraindications include: age over 75, severe heart disease, severe chronic lung disease, other pathologies contraindicating general anesthesia and voice professionals.

Concerning functional results, there is a hierarchy in the functional restoration of the larynx; the resumption of swallowing is a priority, then breathing, finally phonation. The study of the different series of RFAL results in similar functional results [2,12,19].

Compared to other extensive glottic exeresis techniques and their different reconstruction modalities, the RFAL has the advantage of a rapid resumption of swallowing, allowing oral feeding in an average delay of 15 days. Rapid resumption of swallowing stems from the following items: reconstruction using an anterior plasty that preserves the laryngeal height; preservation of upper laryngeal nervous pedicles and the posterior third of the thyroid wings. These latter two characteristics facilitate the elevation of the larynx during swallowing [13].

Zanaret [13] in his series of 137 cases notes that the resumption of swallowing did not show a significant



difference if one or two arytenoids are preserved. Similarly, in our series, for patients who had an exeresis of an arytenoid, the delay of removal of the nasogastric tube was 21 days while it was 18 days when both arytenoids were preserved. Early aspirations are favored by resection of an arytenoid but without statistically significant correlation [21].

For Prades [5], postoperative decannulation depends on normal swallowing resumption. Extended delays (32 days) were found with Schroder [22]. This delay may be explained by the occurrence of pulmonary complications such as aspiration pneumonia during the postoperative period.

Advocates of early decannulation point to the infectious risk of the cannula, and the fact that it promotes swallowing disorders by limiting the rise of the larynx. In addition, it decreases the cough reflex and the mobility of the arytenoids, alters the phonatory and respiratory function. Other teams are in favour of late decannulation after food recovery in order to prevent the risk of aspirations and dyspnea by laryngeal edema [3,23].

The study of the post-RFAL voice must be based on a subjective, an objective as well as a morphological evaluation (using a video laryngoscopy) to better assess the phonatory results of this type of surgery [23,24]. Mendenhall [25]proposed a pre-therapeutic and post-therapeutic evaluation of the voice (12 months after treatment). Nevertheless, no vocal evaluation of phonation has been universally validated; although different functional voice evaluation protocols have been proposed by many authors based on acoustic,

perceptual, aerodynamics and morphological ones, including self-assessment. The voice handicap index (VHI) is the most widely used questionnaire for self-assessment of the voice [24, 25,26].

It should be noted that speech therapy in postoperative setting is necessary to improve voice quality as well as swallowing [24].

Oncological results are evaluated based on local, lymph node and distant metastatic recurrences, and on survival: the local control rate at 5 years after RFAL varies in the literature from 83% to 100% In our series, there was only one case of loco-regional recurrence occurring four years after initial treatment in a patient with glottic cancer with involvement of the anterior commissure and the floor of the ventricle. Concomitant radio-chemotherapy was indicated. The patient later died of his illness.

Monitoring is based primarily on clinical and endoscopic examination of the neolarynx. For Zbaren[28], MRI with diffusion sequences and its high resolution of soft parts makes it easier to detect tumor recurrences in the levels of laryngeal tissues modified by radiotherapy or surgery. Management of local or loco regional failure is a total salvage laryngectomy followed by post-operative radiotherapy for some authors[3,10,11,13]. Radiotherapy alone may be offered in case of minimal recurrence or refusal of total laryngectomy [10].

Several series studied long-term oncological results (5-10 years). All of these studies found high survival rates after RFAL at all stages[3,12]. The overall 5-year survival rate ranges from 81.5% to 100%, and specific survival ranges from 86% to 96.9% [10,12].

**Table 1 summarizing some RFAL series from the literature**

Authors	Number of patients	Indications	Decannulation (days)	NG tube removal (days)	Local control	survival
Tucker 1979[2]	10	Salvage surgery after radiotherapy : 7	12(8-17)	10(1-18)	100%	100%
Tücker 1989[10]	48	T1a : 4 T1b : 8 T2 : 8 T3 : 11 Salvage surgery: 22 -radiotherapy : 12 -surgical or laser cordectomy:5 -radiotherapy+ surgery : 5	-	-	-Recurrence: 8 5 local recurrence 3 lymph node recurrences	25% 12 deaths : -2: laryngeal cancer -6:neoplasm other than laryngeal -4: non-neoplastic causes
Zanaret 1993[13]	57	T1 : 15 T2 : 42	12(5-22)	15(9-31)	T1 : 93% T2 :79%	-T1 : 80% 2 deaths:unrelated causes -T2 : 78.6% 3 unrelated causes 1 local and lymph node recurrence
Mallet 2001[3]	65	T1a : 16 T1b :30 T2 : 19	18	12	-Recurrence : 4 2 local recurrence 2 lymph node recurrence	82%
Giovianni 2001[19]	127	T1 : 62 T2 : 65	11(5-22)	15(7-31)	94% T2 : 5 local recurrence and 3 lymph node recurrence	T1 : 91% T2 : 86% 3 deaths after local recurrence
Akyilidiz 2015[29]	68	T1a : 4 T1b : 43 T2 : 21	12	10	6 failures (medium of 37 months) 5T1b, 1T2 4 : local recurrence 1 lymph node recurrence	Global survival T1b 97.5% T2 100% Specific survival : 5 %93.5 years
Our series 2020	32	T1a : 18 T1b : 7 T2 : 7	19(11-52)	20(10-33)	96.7 % 1 local recurrence after 4 years	96.7 % 1 death



## CONCLUSION:

Early stage glottic carcinoma is a highly curable disease. RFAL with epiglottic reconstruction laryngectomy is a valuable technique in selected glottic carcinomas. Based on our results, this procedure's local control and survival rates are high with satisfying functional results. Even it is no longer the standard after the development of endoscopic laser surgery, transoral robotic surgery, radiotherapy, RFAL remains reliable in precise indications such as Difficulty of laryngeal exposure for tran-

soral approach and lack of technical platform for laser or robotic laryngeal surgery..

## Compliance with ethical standards

**Conflict of interest:** The authors stated that there is no conflict of interest.

**Funding Statement:** The authors received no specific funding for this work.

## REFERENCES:

- Schultz P. Vocal fold cancer. *Eur Ann Otorhinolaryngol Head Neck Dis.* 2011; 128(6):301-8.
- Tucker HM, Wood BG, Levine H, Katz R. Glottic reconstruction after near total laryngectomy. *The Laryngoscope.* 1979;89(4):609-18.
- Mallet Y, Chevalier D, Darras JA, Wiel E, Desauty A. Near total laryngectomy with epiglottic reconstruction: our experience of 65 cases. *Eur Arch Oto-Rhino-Laryngol Off J Eur Fed Oto-Rhino-Laryngol Soc EUFOS Affil Ger Soc Oto-Rhino-Laryngol - Head Neck Surg.* 2001;258(9):488-91.
- AJCC Cancer Staging Manual Eighth Edition. <https://cancerstaging.org/references-tools/deskreferences/Documents/AJCC%20Cancer%20Staging%20Form%20Supplement.pdf> consulté le 09/11/2020.
- Prades JM, Martin C, Garban T, Perron X, Mayaud R. Reconstructive laryngectomies. Technical and functional aspects. *Ann Oto-Laryngol Chir Cervico Faciale Bull Soc Oto-Laryngol Hopitaux Paris.* 1987; 104(4):281-7.
- Jadeed R, Westhofen M.. Outcomes of frontolateral vertical partial laryngectomy in T1b glottic carcinomas. *Acta Otolaryngol.* 2021;141(1):99-105.
- Allegra E, Lombardo N, La Boria A, et al. Quality of voice evaluation in patients treated by supracricoid laryngectomy and modified supracricoid laryngectomy. *Otolaryngol Head Neck Surg.* 2011;145(5):789-795
- M. Moulin, C.A. Righini, P.F. Castellanos, I. Atallah. Epiglottoplasty technique in endoscopic partial laryngectomy. *Eur Ann Otorhinolaryngol Head Neck Dis.* 2018; 135:197-199.
- Kayhan FT, et al. Oncological outcomes of early glottic carcinoma treated with transoral robotic surgery. *Auris Nasus Larynx.* 2019; 46(2): 285-293..
- Tucker HM, Benninger MS, Roberts JK, Wood BG, Levine HL. Near-total laryngectomy with epiglottic reconstruction. Long-term results. *Arch Otolaryngol Head Neck Surg.* 1989;115(11):1341-4.
- Piquet JJ, Chevalier D, Darras JA, Roux X. Laryngectomy with Tucker's epiglottoplasty. *Ann Oto-Laryngol Chir Cervico Faciale Bull Soc Oto-Laryngol Hopitaux Paris.* 1990;107(8):555-8.
- Lawson G, Jamart J, Remacle M. Improving the functional outcome of Tucker's reconstructive laryngectomy. *Head Neck.* 2001;23(10):871-8.
- Zanaret M, Giovanni A, Gras R, Cannoni M. Near total laryngectomy with epiglottic reconstruction: long-term results in 57 patients. *Am J Otolaryngol.* 1993;14(6):419-25.
- Chawla S, Carney AS. Organ preservation surgery for laryngeal cancer. *Head Neck Oncol.* 2009;1:12.
- Perrin C, Brunet A, Apap E. Frontal anterior laryngectomy with sliding epiglottoplasty. Tucker's operation. Indications. Technic and results. *Ann Oto-Laryngol Chir Cervico Faciale Bull Soc Oto-Laryngol Hopitaux Paris.* 1987; 104(4):277-9.
- Nie C, Shen C, Hu H, Ma Y, Wu H, Xiang M. Mid-term results of frontoververtical partial laryngectomy for early glottic carcinoma with anterior commissure involvement. *Acta Otolaryngol (Stockh).* 2014; 134(4):407-12.
- Lei W, Jiang A, Chai L, Zhu X, Wang Z, Wen Y, et al. Middle Frontal Horizontal Partial Laryngectomy (MFHPL): A Treatment for Stage T1b Squamous Cell Carcinoma of the Glottic Larynx Involving Anterior Vocal Commissure. *PLoS One.* 2013; 8(1): e52723.
- Bradley PJ, Rinaldo A, Suárez C, Shaha AR, Leemans CR, Langendijk JA, et al. Primary treatment of the anterior vocal commissure squamous carcinoma. *Eur Arch Oto-Rhino-Laryngol Off J Eur Fed Oto-Rhino-Laryngol Soc EUFOS Affil Ger Soc Oto-Rhino-Laryngol - Head Neck Surg.* 2006;263(10):879-88.
- Giovanni A, Guelfucci B, Gras R, Yu P, Zanaret M. Partial frontolateral laryngectomy with epiglottic reconstruction for management of early-stage glottic carcinoma. *The Laryngoscope.* 2001;111(4 Pt 1):663-8.
- Başerer N. Frontoanterior supracricoid laryngectomy with epiglottoplasty. *Tr-ENT* 2019;29(2):86-93.
- Brasnu D, Laccourreye O, Hans S, Menard M, De Mones E, Behm E. Chirurgie et cancer du larynx. Monographie Amplifon édition 2005.
- Schröder U, Eckel HE, Jungehülsing M, Thumfart W. Indications, technic and results following Sedlacek-Kambic-Tucker reconstructive partial resection of the larynx. *HNO.* 1997;45(11):915-22.
- Oysu C, Aslan I. Cricohyoidoepiglottopexy vs near-total laryngectomy with epiglottic reconstruction in the treatment of early glottic carcinoma. *Arch Otolaryngol Head Neck Surg.* 2006;132(10):1065-8.
- Dejonckere PH, Bradley P, Clemente P, Cornut G, Crevier-Buchman L, Friedrich G, et al. A basic protocol for functional assessment of voice pathology, especially for investigating the efficacy of (phonosurgical) treatments and evaluating new assessment techniques. Guideline elaborated by the Committee on Phoniatrics of the European Laryngological Society (ELS). *Eur Arch Oto-Rhino-Laryngol Off J Eur Fed Oto-Rhino-Laryngol Soc EUFOS Affil Ger Soc Oto-Rhino-Laryngol - Head Neck Surg.* févr 2001;258(2):77-82.
- Mendenhall WM, Takes RP, Shah JP, Bradley PJ, Beitler JJ, Strojanc P, et al. Current treatment of T1N0 squamous cell carcinoma of the glottic larynx. *Eur Arch Oto-Rhino-Laryngol Off J Eur Fed Oto-Rhino-Laryngol Soc EUFOS Affil Ger Soc Oto-Rhino-Laryngol - Head Neck Surg.* 2015;272(8):1821-4.
- Malki KH, Mesallam TA, Farahat M, Bukhari M, Murry T. Validation and cultural modification of Arabic voice handicap index. *Eur Arch Oto-Rhino-Laryngol Off J Eur Fed Oto-Rhino-Laryngol Soc EUFOS Affil Ger Soc Oto-Rhino-Laryngol - Head Neck Surg.* nov 2010;267(11):1743-51.
- Seifpanahi S, Jalaie S, Nikoo MR, Sobhani-Rad D. Translated Versions of Voice Handicap Index (VHI)-30 across Languages: A Systematic Review. *Iran J Public Health.* avr 2015;44(4):458-69.
- Zbären P, Weidner S, Thoeny HC. Laryngeal and hypopharyngeal carcinomas after (chemo)radiotherapy: a diagnostic dilemma. *Curr Opin Otolaryngol Head Neck Surg.* 2008; 16(2):147-53.
- Akyildiz S, Ozturk K, Turhal G, Gode S, Kirazli T, Uluoz U. Post-surgical and Oncologic Outcomes of FrontalAnterior Laryngectomy with Epiglottic Reconstruction: A review of 68 cases, *Otolaryngol Head Neck Surg.* 2015; 36(3):371-76.