

Pediatric lipoblastoma of the infratemporal fossa: A case report

Lipoblastome pédiatrique de la fosse infratemporale: À propos d'un cas

M. Dhaha, S. Ferchichi, S. Dhambri, S. Jbali, M. Moula, M. Ben Amira, S. Kedous, S. Touati, S. Gritli

Head and Neck surgery Department Salah Azaez Oncology Institute, Tunis

Received: 06 December 2020, Accepted: 15 January 2021, Published online: 30 April 2021

ABSTRACT

Objectives: Our purpose was to present the clinical, radiological and histological features of head and neck lipoblastoma and its management by studying an illustrative rare case of lipoblastoma occurring in the infratemporal fossa.

Observation: we report a rare case of lipoblastoma of the infratemporal fossa in a 3 year-old boy presenting as an oropharyngeal rapidly-growing mass evolving for 4 months. Magnetic Resonance Imaging (MRI) showed an 11-centimeter tumor of the infratemporal fossa and the right parapharyngeal space with high-intensity T1 signal. The child underwent total surgical resection of the tumor through an external cervical approach. The post-operative recovery was simple. No recurrence was recorded after 2 years of follow-up.

Conclusion: Lipoblastomas of the head and neck are extremely rare. Imaging especially MRI is helpful for the diagnosis and the preoperative evaluation. Total surgical resection is the best treatment to avoid recurrence. However, the vulnerability of the neurovascular structures in the head and neck remains a great challenge for the surgeon.

Key-words: Lipoblastoma, infratemporal fossa, child, MRI

RÉSUMÉ

Objectif: Notre objectif était de présenter les caractéristiques Cliniques, radiologiques et histologiques du lipoblastome dans sa localisation cervico faciale ainsi que sa prise en charge en étudiant un cas illustratif rare localisé à la fosse infratemporale.

Observation: nous rapportons le cas d'un enfant âgé de 3 ans qui s'est présenté avec une formation oropharyngée augmentant rapidement de volume évoluant depuis 4 mois. L'imagerie par résonance magnétique (IRM) a montré une formation au dépend de la fosse infratemporale et de l'espace parapharyngé droit en hyper signal T1. L'enfant était opéré par voie externe cervicale permettant l'exérèse totale de la tumeur. Les suites opératoires étaient simples. Le patient n'a pas présenté de récurrence durant les 2 ans de suivi.

Conclusion: les lipoblastomes de la tête et du cou sont extrêmement rares. L'imagerie, en particulier l'IRM est d'un grand apport pour le diagnostic et la prise en charge. La résection chirurgicale totale reste le meilleur traitement permettant d'éviter les récurrences. Par ailleurs, la complexité anatomique de la région cervico faciale reste un grand défi pour le chirurgien.

Mot-clés: Lipoblastome, Fosse infratemporale, Enfant, IRM

INTRODUCTION:

Lipoblastoma is a benign rapidly-growing neoplasm of the white fat tissue that occurs almost exclusively in infants under 3 years. It usually arises from the trunk and extremities. The head and neck region is an uncommon site for Lipoblastomas [1]. They are divided into 2 types; the more common encapsulated form known as Lipoblastoma and the diffuse form known as lipoblastomatosis [2]. Although surgical management is curative in most cases, Lipoblastoma exhibits a relatively high recurrence rate [3]. We report a case of

a lipoblastoma of the infratemporal fossa in a 3 year-old boy surgically removed with a cervical approach. Our purpose was to present the clinical and histological features of this rare site of Lipoblastoma.

OBSERVATION:

A 3 year-old boy was referred by his pediatrician to the department of head and neck surgery of our Institute for a rapidly-growing oropharyngeal mass evolving for 4 months. No past medical history was noted. Clinical examination found a soft painless mass of the right



lateral pharyngeal wall extended to the right hemi palate and the retromolar trigone. No cervical mass was noted. Cervico facial CT scan showed a lobular heterogeneous hypodense mass with fatty and tissular components. This mass occupied the infratemporal fossa and the right parapharyngeal space (Figure 1). Magnetic resonance imaging (MRI) showed an 11-centimeter formation of the infra temporal fossa and the right parapharyngeal space with high-intensity T1 signal (Figure 2). Many areas disappeared with T1-weighted fat suppression sequences. This description was compatible with a Lipoblastoma. Surgical excision was performed through an external approach. A classical Blair parotidectomy incision was realized. The overlying skin flap was raised. The external jugular vein was cut and ligatured. The anterior border of the sternocleidomastoid muscle was recliné. The posterior side of the gland was approached. The main trunk of the facial nerve and the cervico facial branch were identified and dissected. The tumor was exposed. It was a parapharyngeal greasy multinodular mass deeper than the parotid gland. A piecemeal resection was performed after meticulous dissection due to the large size of the tumor (Figures 3 and 4). No particular bleeding was noted. A drain was inserted and kept for 3 days. The Intraoperative frozen sections examination concluded a mesenchymal tumor. The post-operative recovery was simple. No facial nerve palsy was noted. The patient was discharged 3 days after the intervention. Histological examination confirmed the diagnosis of Lipoblastoma. A regular follow up every 3 months based on clinical examination was performed. No recurrence was recorded after 2 years of follow-up.

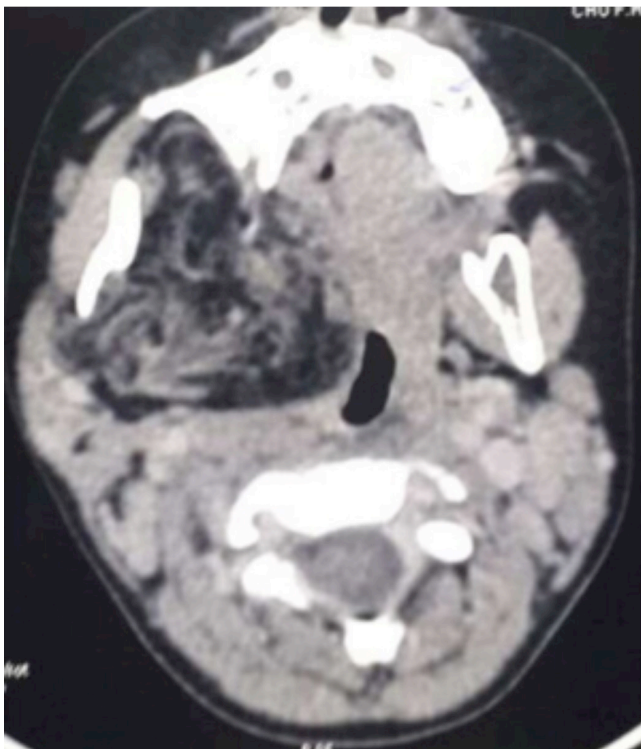


Figure 1: CT scan axial section showing heterogeneous hypodense of the infratemporal fossa

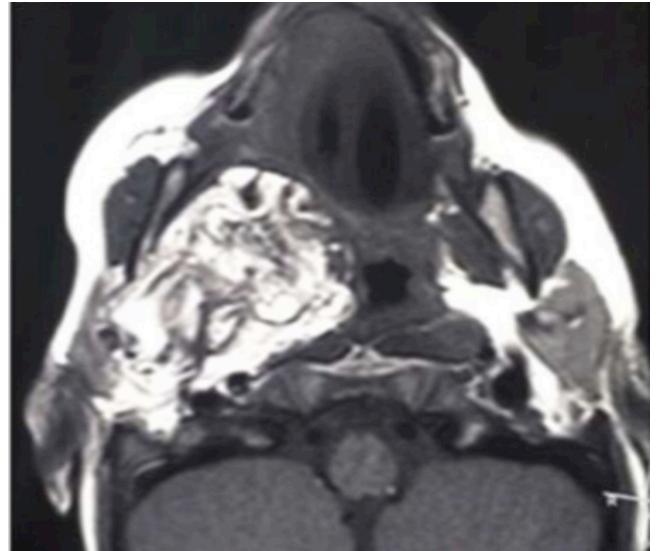


Figure 2: facial T1-weighted MRI axial section showing a high intensity mass of the right infratemporal fossa and the parapharyngeal space

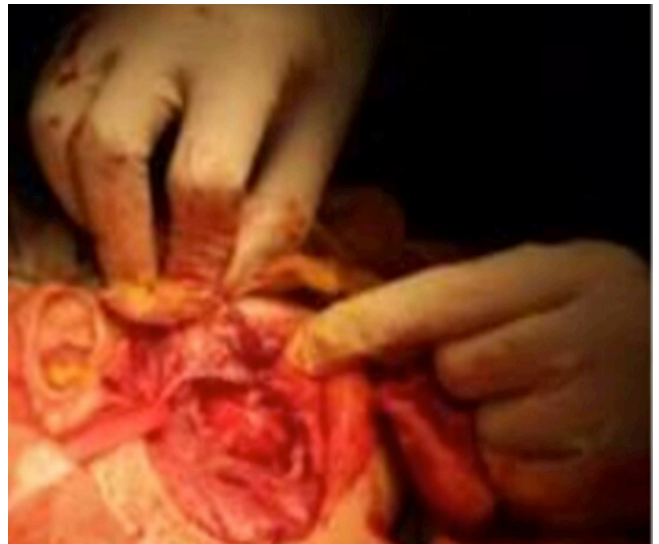


Figure 3: facial T1-weighted MRI axial section showing a high intensity mass of the right infratemporal fossa and the parapharyngeal space

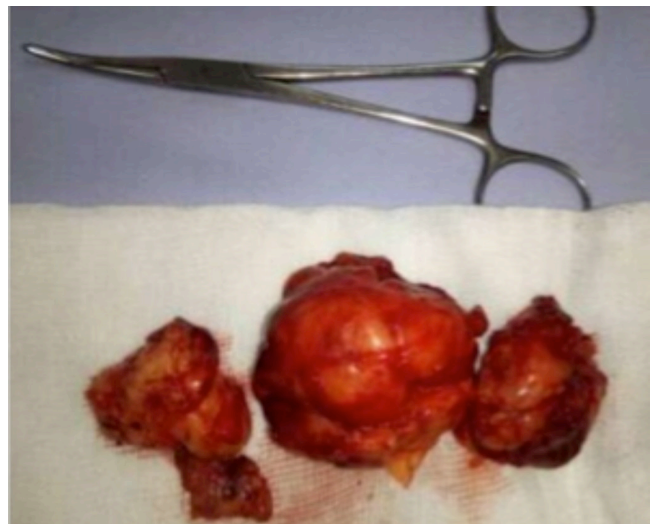

Figure 4: Surgical specimen



DISCUSSION:

Lipoblastoma was first described in 1924 by Jaffe as a benign tumor of immature fat cells characterized by well encapsulated and localized mass [4]. Lipoblastomatosis is the term used for the multicentric diffuse form of Lipoblastoma.

Like in this case, lipoblastomas usually occurs in infants and children. About 90% of the reported cases are under the age of 3 years [3]. Male predominance was reported in most of the series [3, 5, 6]

Lipoblastomas are rare and limited in the literature to scattered case reports and small series [5-7]. These mesenchymal tumors commonly arise from the extremities (30-70%) and the trunk (20-50%) and were rarely described in the head and neck [1]. Probably the largest review of the English literature of head and neck lipoblastoma was reported by Pham et al [5]. It included 48 reported cases. The cervical region is the most common site for head and neck Lipoblastomas [5]. The parotid gland, the cheek, the orbit, and the skin were less commonly reported [5]. The infratemporal fossa like in this case is an exceptional location. To our knowledge, only 2 similar cases were recorded. A case reported by Najib et al [8] in a 7 year-old boy who presented with a right temporomandibular swelling. The second observation was reported by Ananthranjan who described a huge lipoblastoma of the parotid gland and infratemporal fossa [9]. Like in this case, lipoblastoma usually presents as a rapidly growing painless mass. However, as the tumor progresses, different symptoms could manifest depending on the location in the head and neck region. Airway obstruction resulting in stridor and dyspnea has been reported [6]. Upper extremities weakness was recorded by the same authors [6, 7]. In a similar case of lipoblastoma of the infratemporal fossa reported by Najib et al, the patient presented with an isolated painless temporomandibular swelling [8].

Histologically, lipoblastoma is composed of immature lipoblasts at different stages of maturity and mesenchymal cells separated with septae. The myxoid matrix often seen in lipoblastoma could be misleading due to its similarity with the myxoid liposarcoma. In some suspicious cases, cytogenetic analysis is helpful. Cytogenetic breakpoint abnormalities occur in chromosome 8q11-13 in lipoblastomas while a translocation (12-16) is seen in myxoid liposarcomas [10].

The distinction between lipomatous tumors on basis of imaging is difficult. No pathognomonic features were attributed to lipoblastoma. Lipoblastomas are usually radioopaque and none enhancing on CT scan [5]. In this case, CT, scan showed a hypodense heterogeneous lesion. MRI is more helpful in studying the tumor extent and composition. Lipoblastoma manifests with hyper signal on both T1 weighted and T2 weighted images. The T1 signal is lower than the subcutaneous fat due to the immature nature of cells of lipoblastomas. This

feature could distinguish between lipoblastoma and lipomas. Besides, MRI shows the myxoid and fibrous components of the tumor which define the T2 signal intensity.

In this case, lipoblastoma was managed surgically using an external approach. In fact this approach allowed an optimal exposure of the tumor. The transoral approach was avoided in this case due to narrow buccal cavity and the large size of the tumor. The tumor was encapsulated and didn't adhere to the adjacent structures which facilitate its removal. The tumor was resected in a piecemeal fashion due to its large size. Otherwise, Najib et al [8] treated an infratemporal lipoblastoma in a 7 year-old child using a temporal approach. Local recurrences were reported in 8 to 25% of cases [3, 6]. It's usually related to incomplete resection. Therefore a regular follow up 3 to 5 years is recommended [3]. However, According to Pham et al [5], highly morbid surgical resection should be avoided due to the lack of malignant transformation and possible spontaneous regression. Instead, a wait and see policy with possible MRI monitoring was proposed [5]. Subtotal resection has been also proposed especially in the head and neck location due to the vulnerability of the neurovascular structures compared to the trunk and extremities.

CONCLUSION:

Lipoblastoma is a benign neoplasm of immature fat tissue occurring in infants. The head and neck location are relatively rare and usually manifest as a painless growing mass. Imaging, especially MRI, is helpful in diagnosis and preoperative evaluation. Careful pathologic examination could avoid unnecessary cytogenetic analysis.

Total surgical resection is the best treatment. Subtotal resection and "wait and see policy" may be discussed for highly morbid intervention especially in the head and neck location due to vulnerable neurovascular structures.

Compliance with ethical standards

Conflict of interest: The authors stated that there is no conflict of interest.

Funding Statement: The authors received no specific funding for this work.

**REFERENCES:**

1. Camilleri AC, Smith WP, Kaiser L. Infantile cervical lipoblastoma: a case report and review of the literature. *J oral maxillofac surg.* 2004;62(3):383-6.
2. Shah AR, Wei JL, Maddalozzo J. Cervical lipoblastoma: an uncommon diagnosis of neck mass. *Otolaryngol Head and neck surg.* 2004;130(4):504-7.
3. Speer AL, Schofield DE, Wang KS, Shin CE, Stein JE, Shaul DB, et al. Contemporary management of lipoblastoma. *J Pediatr surg.* 2008;43(7):1295-300.
4. Jaffe R. Recurrent lipomatous tumors of the groin: liposarcoma and lipoma pseudomyxomatodes. *Arch Pathol.* 1926;1:381-7.
5. Pham NS, Poirier B, Fuller SC, Dublin AB, Tollefson TT. Pediatric lipoblastoma in the head and neck: a systematic review of 48 reported cases. *Int J Pediatr otorhinolaryngol.* 2010;74(7):723-8.
6. Susam-Sen H, Yalcin B, Kutluk T, Cahit Tanyel F, Haliloglu M, Orhan D, et al. Lipoblastoma in children: Review of 12 cases. *Pediatr Int.* 2017;59(5):545-50.
7. Vo NH, Mashiana MK, Vo CC, Ward K, Nguyen J. Atypical Presentation of Lipoblastoma of a 9-Month-Old. *Ear Nose Throat J.* 2019;98(5):261-2.
8. Najib J, Aniba K, Laghmari M, Lmejjati M, Ghannane H, Benali SA, et al. Lipoblastoma of the subtemporal fossa. *Pan Afr Med J.* 2014;19:323.
9. Anantharajan N, Ravindranathan N. Parotid lipoblastoma in a child: Rare presentation as huge infratemporal mass with cervical extension. *Indian J Plast Surg.* 2010;43(1):84-7.
10. Miller GG, Yanchar NL, Magee JF, Blair GK. Tumor karyotype differentiates lipoblastoma from liposarcoma. *Journal of pediatric surgery.* 1997;32(12):1771-2.